

Indication for exam:

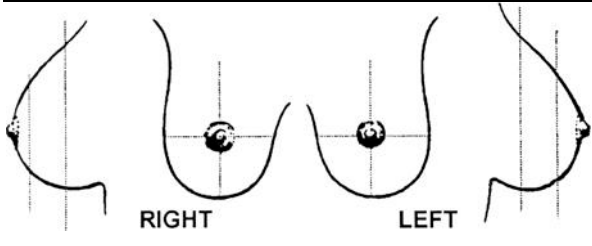
Screening (asymptomatic)

Diagnostic (symptomatic)

Tech _____

Additional evaluation of recent exam

Short interval follow-up



Technologist Remarks:

Views: Bilateral R L CC MLO LM ML Spot Comp Mag Push/pull Other: _____

Dictation involved **Tissue Density:** Very dense Heterogeneously dense Scattered fibroglandular Fatty

There _____ cm _____ density
is a are multiple benign-appearing suspicious high equal low radiolucent

_____ nodule mass density architectural distortion
round oval lobulated irregular reniform

with _____ margins
well-defined circumscribed microlobulated ill-defined indistinct obscured spiculated

in the _____ breast(s) _____ :00 _____ position _____
right left both subareolar anterior posterior middle central axillary tail which is/are stable.

There _____
is a are benign-appearing suspicious scattered regional clustered

_____ calcification(s)
round linear vascular coarse rod-like heterogeneous punctate amorphous milk-of-calcium indistinct branching

in the _____ breast(s) _____ :00 _____ position _____
right left both subareolar anterior posterior middle central axillary tail which is/are stable.

Other Comments:

No discrete abnormality
 No change from previous

Prior studies unavailable
 Focal asymmetric density

Asymmetric breast tissue Breast implants are intact

Prior Studies: From _____ on ___/___/___; from _____ on ___/___/___.

Impression

- Negative
- Benign finding(s)
- Probably benign finding
- Suspicious abnormality
- Highly suspicious
- Incomplete-needs additional evaluation

Recommendation

- F/U mamm in _____ yr _____ mo at age 40 per ACS guidelines back on schedule
- Special view(s); R L Spot Compression Mag CC MLO LM ML Cleopatra
- Clinical correlation with attention to _____
- Ultrasound R L _____
- Repeat Film(s) _____
- Cyst aspiration _____
- Surgical consult _____
- Other _____

Read ___/___/___

By: JA GA BA RB GB CC RC KDK
FL HN PP RP GS MS RS JW